

# Osteomyelitis due to multiple rare infections in a patient with idiopathic CD4 lymphocytopenia

Nitin Gupta<sup>1</sup>, Sayantan Banerjee<sup>1</sup>, Timitrov<sup>2</sup>, Rohini Sharma<sup>2</sup>, Shambo Guha Roy<sup>3</sup>,  
Trupti M Shende<sup>4</sup>, Mohammed Tahir Ansari<sup>5</sup>, Gagandeep Singh<sup>4</sup>, Neeraj Nischal<sup>2</sup>,  
Naveet Wig<sup>2</sup>, Manish Soneja<sup>2,\*</sup>

<sup>1</sup>Infectious Disease Division, Departments of Medicine and Microbiology, All India Institute of Medical Sciences, New Delhi, India;

<sup>2</sup>Department of Medicine, All India Institute of Medical Sciences, New Delhi, India;

<sup>3</sup>Department of Nuclear Medicine, All India Institute of Medical Sciences, New Delhi, India;

<sup>4</sup>Department of Microbiology, All India Institute of Medical Sciences, New Delhi, India;

<sup>5</sup>Department of Orthopaedics, All India Institute of Medical Sciences, New Delhi, India.

## Summary

A 26-year-old male patient presented with features suggestive of osteomyelitis involving the entire left femur, hip joint and knee joint. Culture from the debrided tissue grew *Acinetobacter spp.* and he was treated with sensitivity based antibiotics but the symptoms did not resolve. The synovial biopsy showed multinucleated giant cells and acid fast bacilli on Ziehl Neelsen stain. Cartridge based nucleic acid amplification test (GeneXpert) was negative. The Mycobacteria growth indicator tube culture was found to be positive for *Mycobacterium abscessus*. The patient was started on imipenem, amikacin and macrolide based therapy. There was partial response initially but the patient worsened again. A girdle stone arthroplasty with cemented nail (with tobramycin) insertion after debridement of the infected tissue was done. Potassium hydroxide (KOH) mount from the debridement sample was found to be positive for aseptate hyphae suggestive of mucormycosis. He was treated with liposomal amphotericin B. He was evaluated for immunodeficiency in view of multiple atypical infections and was found to have a low CD4 count. The patient was discharged on amikacin, azithromycin, trimethoprim-sulfamethoxazole and posaconazole. Follow up showed considerable resolution both clinically and radiologically. To our knowledge, this is the first reported case of osteomyelitis with co-infection of *Acinetobacter spp.*, *M. abscessus* and mucormycetes. We report this case to highlight the possibility of multiple rare infections in patients with immunodeficiency. Also, atypical complicated bone infections, such as *Mycobacterium abscessus* and mucormycetes might require combined medical and surgical treatment.

**Keywords:** *Acinetobacter spp.*, *Mycobacterium abscessus*, mucormycetes

## 1. Introduction

Osteomyelitis is a chronic debilitating illness requiring a combination of long term medical and surgical treatment. The most commonly implicated organisms

are gram positive cocci like *Staphylococcus aureus* (1). Atypical organisms can be suspected in immunodeficient patients or those not responding to the initial choice of antimicrobials. Idiopathic CD4 lymphocytopenia (ICL) is defined as CD4 count below 300 cells/uL on two occasions 3 months apart (2). In a review published in 2013, 259 cases of ICL were reported between 1989 and 2012 (3). Infections with nontuberculous mycobacteria (NTM) and fungi are far more common in ICL than in immunocompetent individuals (3). *Mycobacterium abscessus* is a rare cause of osteomyelitis with only few reported cases in the published literature (4). Similarly, bone mucormycosis is an extremely rare entity with

Released online in J-STAGE as advance publication July 28, 2017.

\*Address correspondence to:

Dr. Manish Soneja, Department of Medicine, 3rd Floor, Teaching block, All India Institute of Medical Sciences, New Delhi 110029, India.

E-mail: manishsoneja@gmail.com

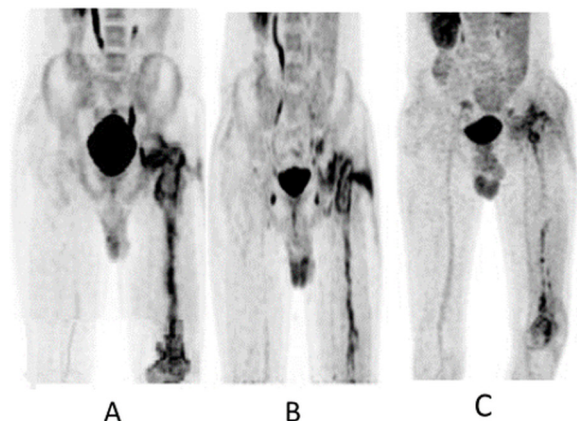
only 34 reported cases according to a systematic review (5). We present a case who was unlucky enough to have multiple rare infections associated with osteomyelitis in a backdrop of idiopathic CD4 lymphocytopenia.

## 2. Case Report

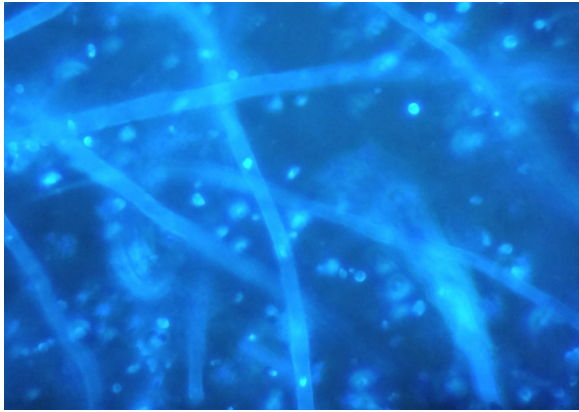
A 26-year-old male patient presented with pain in left thigh and restriction of movement of left hip joint with low grade fever for seven days to a local hospital in March, 2015. There was no antecedent history of trauma, recurrent infections, or intravenous (IV) drug abuse. He had a past history of left middle cerebral artery infarct (possible cause: protein S deficiency/anti-thrombin III deficiency) in 2013 and recovered without residual paralysis. He was immunized with BCG (Bacillus Calmette Guerin) vaccine at birth. On examination, the patient was well built and nourished. His vitals were stable. There was restriction of movement in the left hip joint but the systemic examination was normal. The non-contrast computed tomography (NCCT) scan of thigh showed normal bone anatomy but multiple fluid collections in adjacent muscles. With a provisional diagnosis of septic arthritis, hip arthrotomy and drainage was performed. The synovial fluid examination showed 13,400 cells (97% Neutrophils) and the culture was sterile. He received empirical intravenous antibiotics for one month but his symptoms persisted. He also developed discharging sinus at the surgical site. In April 2015, the patient visited a tertiary care hospital. Debridement of hip joint was done and culture from the debrided tissue grew *Acinetobacter spp.* which was sensitive to only tigecycline, colistin and meropenem. The patient received tigecycline, meropenem and linezolid for one month but symptoms did not resolve. In May 2015, he developed new onset pain and swelling in the left knee joint. Arthrotomy with partial synovectomy was done. The synovial biopsy showed lymphoplasmocytic infiltration with foamy histiocytes along with micro abscess and occasional multinucleated giant cells. The biopsy was positive for acid fast bacilli (AFB) on Ziehl Neelsen (ZN) stain but Gene Xpert (Cartridge based Nucleic acid amplification test) was negative. The patient was discharged on Category 1 Anti-tubercular therapy (Rifampicin, isoniazid, pyrazinamide and ethambutol).

The patient was wheel chair bound when he presented to our hospital in October 2015 with persistent pain in left hip and knee joint and multiple discharging sinuses over the lateral aspect of thigh and knee. On examination, his left hip and knee joint were swollen and tender with partial restriction in range of movement. Multiple discharging sinuses were present in the left hip and knee joints. Complete haemogram, routine blood chemistry and chest X-ray were within normal limits. Tuberculin sensitivity testing was positive. Bone scan showed chronic osteomyelitis involving the entire left

femur. A debridement of hip and knee joint was done. A cavity was seen in the greater trochanter and lateral condyle of femur intraoperatively. The patient underwent multiple debridements and received multiple intravenous antibiotics along with anti-tubercular therapy (ATT) for two months. Repeat bone scan showed partial response. A diagnosis of chronic osteomyelitis refractory to sensitivity based antibiotics and ATT was made. The following possibilities were kept for the etiology: Non tuberculous Mycobacteria (NTM), multi-drug resistant tuberculosis (MDR TB), deep seated bacterial infection and fungal infection. The discharge from the sinuses were sent for bacterial and fungal culture, both of which turned out to be sterile. HBsAg, Anti HCV and HIV serology were nonreactive. Urine and Blood culture were sterile. Histopathological examination of the debrided tissue showed multinucleated giant cells. Both AFB and Gene Xpert were negative this time. A provisional diagnosis of NTM osteomyelitis was made. The patient was discharged in January, 2016 on Category 1 ATT along with clarithromycin. The Mycobacteria growth indicator tube (MGIT 960) culture reports were awaited at the time of discharge. The patient was lost to follow-up and presented to us again in June, 2016 with non-resolving symptoms. MGIT Culture reports were traced to be positive in three of the debridement tissue samples. The MGIT culture was identified as NTM by detecting the MPT 64 antigen using the immunochromatography technique. The 16 S rRNA was sequenced and was identified as *Mycobacterium abscessus* (GenBank: KX343025.1). It was sensitive to both clarithromycin (Minimum inhibitory concentration less than equal to 1) & amikacin (Minimum inhibitory concentration less than equal to 16). Fluorodeoxyglucose positron emission tomography (FDG PET) scan was performed which was consistent with features of Chronic osteomyelitis of left femur (Figure 1A). The patient was started on imipenem (1g IV TDS), amikacin (500 mg IV OD), clarithromycin



**Figure 1. Fluorodeoxyglucose positron emission tomography (FDG PET). (A),** Serial scans showing evidence of osteomyelitis in June, 2016. **(B),** Partial resolution in October, 2016; **(C),** Near complete resolution in April, 2017.



**Figure 2. Calcofluor white – Potassium hydroxide (KOH) mount.** Microscopy at 400× magnification showing broad aseptate hyphae in debridement sample suggestive of invasive mucormycosis.

(500 mg BD oral) and rifabutin (300 mg OD). In October 2016, a repeat FDG PET was performed which showed no resolution (Figure 1B). Clarithromycin was replaced with azithromycin. A girdle stone arthroplasty was performed and an antibiotic impregnated nail (2 gm tobramycin into 40 g of cement.) was inserted intramedullary into the femur. The goal of this surgery was to decrease the disease load, to provide high dose of antibiotics locally, excision of sinus tracts and to get a tissue sample for further investigations. Although, the tissue was negative for bacterial and mycobacterial cultures, KOH turned out to be positive for aseptate hyphae suggestive of mucormycosis (Figure 2). Liposomal amphotericin B (300 mg IV OD) was started. Since the patient was having a multitude of different infections, the patient was evaluated for immunodeficiency. HIV ELISA and HIV RNA were negative. His T cell markers were as follows: CD4+ (20.8%), CD8+ (70.8%) and CD4:CD8 (0.3). Absolute CD4+ count was 113 cells/mm<sup>3</sup> (Normal range: 500-1,500 cells/mm<sup>3</sup>). Serum immunoglobulin levels were normal. Natural Killer (NK) cell activity was normal. The frequency of monocytes expressing the MSMD markers (Mendelian Susceptibility to Mycobacterial diseases) were in normal limits. A final diagnosis of NTM osteomyelitis with secondary *Acinetobacter spp.* infection with secondary mucormycosis in a case of primary isolated CD4 lymphocytopenia was made. The patient was discharged in January, 2017 with the following medications: amikacin (500 mg intramuscular OD), rifabutin (300 mg oral OD), azithromycin (500 mg oral OD), trimethoprim-sulfamethoxazole (160 mg/800 mg oral OD) and posaconazole (200 mg oral QID). A follow up in April 2017 showed marked resolution of symptoms. There was partial return in the range of movement in hip and knee joints. A repeat PET scan showed considerable resolution (Figure 1C). A repeat CD4 count which was repeated after 6 months of initial count was 240 cells/mm<sup>3</sup>.

### 3. Discussion

Osteomyelitis is primarily caused by haematogenous spread or direct inoculation of microorganisms (1). In this patient, the initial infection was likely due to haematogenous spread, considering his immunodeficient status and no prior history of trauma. The latter infections may have been nosocomial. The diagnosis of osteomyelitis is primarily dependent on radiological modalities. Although, Magnetic Resonance Imaging (MRI) and Bone scan have high sensitivity and specificity for diagnosis, the most accurate method for diagnosing and excluding osteomyelitis is FDG PET (6,7). The treatment of long bone osteomyelitis can be staged according to the Cierny Mader system (8). According to this system, our patient was categorized as Stage 4 diffuse osteomyelitis. The treatment for stage 4 is a combination of antibiotics and surgical debridement.

In recent years, there has been an increase in gram negative bacilli causing osteomyelitis. These are mostly associated with nosocomial transmission and are very difficult to treat because of antimicrobial resistance (9). There are very few reports of *Acinetobacter spp.* causing osteomyelitis. It has also been suggested based on animal model studies and case series that *Acinetobacter spp.* has a limited role in development of chronic osteomyelitis (10). So, in patients with non-resolving chronic osteomyelitis where *Acinetobacter spp.* grew in culture, possibility of other infections should still be entertained.

NTM is a rare cause of osteomyelitis but they are more commonly seen in immunosuppressed individuals. They should be suspected when ZN staining is positive and Gene Xpert is negative. Culture is essential for the final diagnosis. It is essential to differentiate NTM from MTB complex as it does not respond to conventional ATT. Patients with high suspicion of tuberculosis who do not respond to conventional ATT are often presumptively diagnosed as MDR TB. Comprehensive data from Indian settings are lacking but the isolation rates range from 0.7 to 34% (11-13). In a study from 1998 to 2011, 29 patients were diagnosed with musculoskeletal NTM infection (4). The treatment for NTM osteomyelitis is complicated requiring surgical debridement and long term chemotherapy (14). It is important to identify the NTM up to species level as the management is considerably different for different species. The regimen that is classically used for *M. abscessus* is clarithromycin or azithromycin, amikacin and imipenem or cefoxitin (15). Even though, according to American thoracic society, this regimen is standard for treatment of *M. abscessus*, we also added rifabutin considering the patient was sick. Rifabutin was chosen considering its bactericidal activity, cost, availability and relatively fewer side effects (16). Linezolid could also be added to the primary regimen as it has shown to have good *in-vitro* activity against *M. abscessus*



but we did not add it because long term therapy with linezolid has been associated with high frequency of side effects like myelosuppression and neuropathy. Also, considering a high prevalence of multidrug resistant tuberculosis in India, linezolid is usually kept as a reserve drug. We shifted our patient to azithromycin, when there was inadequate clinical response to the clarithromycin based regimen. *Mycobacterium abscessus* is one of the organisms where clarithromycin is known to induce resistance by the expression of erm (erythromycin resistance methylase) proteins. In comparison, azithromycin causes reduced induction of erm expression (17). There was no discernible change in the status of disease even after switching over to azithromycin. This was the reason he was planned for girdle stone arthroplasty. We used bone cement (PMMA) mixed with tobramycin. To successfully mix antibiotic with cement, the antibiotic has to be heat stable and hydrophilic. Vancomycin, gentamycin, tobramycin, erythromycin and daptomycin have been successfully tried. Using this technique, the antibiotic reaches 10-200 times of the usual bactericidal concentration. There is a sustained release of antibiotics lasting up to four weeks. Those bacteria which do not respond to high serum concentration of antibiotics may respond to this technique due to sustained high concentration of antibiotics at the target site (18). The tissue samples taken during the procedure showed aseptate hyphae. Bone mucormycosis, also a rare entity, is a progressively destructive disease with poor prognosis. The mode of infection is primarily by direct inoculation (trauma or surgery). The mucormycosis in our case was likely to be nosocomially acquired as the patient had multiple post-operative wounds. Bone mucormycosis in general, requires extensive debridement as amphotericin B alone is often not enough. Bone infections due to NTM and Mucormycetes are uncommon entities and are mostly seen in the immunodeficient population. Our patient was found to have idiopathic CD4 lymphocytopenia. Studies have shown that tuberculosis itself can cause transient CD4 lymphocytopenia (19). Such a type of lymphocytopenia would improve with anti-tubercular therapy. In our patient, although there was improvement in the CD4 count when it was repeated it did not go beyond 300 cells/uL. We hypothesized that the patient had initial infection with NTM because the patient had granulomas in the initial synovial biopsy. Also, NTM osteomyelitis is established by haematogenous route while bone infection due to *Acinetobacter spp.* and mucormycosis are mostly described in post-operative nosocomial settings. As mentioned above, *Acinetobacter spp.* has not been conclusively shown as a sole significant cause of osteomyelitis.

The patient was doing well at the follow-up with significant improvement in functional status. In a tertiary care government centre of a resource limited country with an exceedingly heavy load of poor patients, we

were only able to effectively manage the case because of the untiring efforts of the administration, who allowed us to keep the patient admitted for more than a year and provided the expensive investigations and drugs free of cost. Also, the support provided to the treating physicians by the diagnosticians who gave the clues about microbial etiology and the orthopaedicians who performed multiple surgeries was invaluable. In such intractable cases requiring a multimodality approach, active participation from different specialities is warranted for alleviation of long term morbidity and possible mortality.

To conclude, in patients with suspected immunodeficiency, possibility of rare infections should always be kept in mind. Also, multiple infections are far more common in immunodeficient individuals and therefore, they should be searched and managed aggressively. The management in these patients, especially in those with bone infections require proper teamwork between diagnosticians, surgeons and physicians.

## References

1. Lew DP, Waldvogel FA. Osteomyelitis. *Lancet*. 2004; 364:369-379.
2. Gholamin M, Bazi A, Abbaszadegan MR. Idiopathic lymphocytopenia. *Curr Opin Hematol*. 2015; 22:46-52.
3. Ahmad DS, Esmadi M, Steinmann WC. Idiopathic CD4 Lymphocytopenia: Spectrum of opportunistic infections, malignancies, and autoimmune diseases. *Avicenna J Med*. 2013; 3:37-47.
4. Park JW, Kim YS, Yoon JO, Kim JS, Chang JS, Kim JM, Chun JM, Jeon IH. Non-tuberculous mycobacterial infection of the musculoskeletal system: Pattern of infection and efficacy of combined surgical/antimicrobial treatment. *Bone Joint J*. 2014; 96-B:1561-1565.
5. Taj-Aldeen SJ, Gamaletsou MN, Rammaert B, Sipsas NV, Zeller V, Roilides E, Kontoyiannis DP, Henry M, Petraitis V, Moriyama B, Denning DW, Lortholary O, Walsh TJ; International Osteoarticular Mycoses Consortium. Bone and joint infections caused by mucormycetes: A challenging osteoarticular mycosis of the twenty-first century. *Med Mycol*. 2017. [Epub ahead of print]
6. Palestro CJ. Radionuclide Imaging of Musculoskeletal Infection: A Review. *J Nucl Med*. 2016; 57:1406-1412.
7. Wang GL, Zhao K, Liu ZF, Dong MJ, Yang SY. A meta-analysis of fluorodeoxyglucose-positron emission tomography versus scintigraphy in the evaluation of suspected osteomyelitis. *Nucl Med Commun*. 2011; 32:1134-1142.
8. Cierny G 3rd. Surgical treatment of osteomyelitis. *Plast Reconstr Surg*. 2011; 127(Suppl 1):190S-204S.
9. Carvalho VC, Oliveira PR, Dal-Paz K, Paula AP, Félix Cda S, Lima AL. Gram-negative osteomyelitis: Clinical and microbiological profile. *Braz J Infect Dis*. 2012; 16:63-67.
10. Collinet-Adler S, Castro CA, Ledonio CG, Bechtold JE, Tsukayama DT. *Acinetobacter baumannii* is not associated with osteomyelitis in a rat model: A pilot study. *Clin Orthop Relat Res*. 2011; 469:274-282.
11. Jesudason MV, Gladstone P. Non tuberculous mycobacteria isolated from clinical specimens at a tertiary

- care hospital in South India. *Indian J Med Microbiol.* 2005; 23:172-175.
12. Jain S, Sankar MM, Sharma N, Singh S, Chugh TD. High prevalence of non-tuberculous mycobacterial disease among non-HIV infected individuals in a TB endemic country – experience from a tertiary center in Delhi, India. *Pathog Glob Health.* 2014; 108:118-122.
  13. Umrao J, Singh D, Zia A, Saxena S, Sarsaiya S, Singh S, Khatoon J, Dhole TN. Prevalence and species spectrum of both pulmonary and extrapulmonary nontuberculous mycobacteria isolates at a tertiary care center. *Int J Mycobacteriol.* 2016; 5:288-293.
  14. Bi S, Hu FS, Yu HY, Xu KJ, Zheng BW, Ji ZK, Li JJ, Deng M, Hu HY, Sheng JF. Nontuberculous mycobacterial osteomyelitis. *Infect Dis (Lond).* 2015; 47:673-685.
  15. Mougari F, Guglielmetti L, Raskine L, Sermet-Gaudelus I, Veziris N, Cambau E. Infections caused by *Mycobacterium abscessus*: Epidemiology, diagnostic tools and treatment. *Expert Rev Anti Infect Ther.* 2016; 14:1139-1154.
  16. Aziz DB, Low JL, Wu ML, Gengenbacher M, Teo JWP, Dartois V, Dick T. Rifabutin is active against *Mycobacterium abscessus* complex. *Antimicrob Agents Chemother.* 2017; 61:e00155-17
  17. Choi GE, Shin SJ, Won CJ, Min KN, Oh T, Hahn MY, Lee K, Lee SH, Daley CL, Kim S, Jeong BH, Jeon K, Koh WJ. Macrolide treatment for *Mycobacterium abscessus* and *Mycobacterium massiliense* infection and inducible resistance. *Am J Respir Crit Care Med.* 2012; 186:917-925.
  18. Cancienne JM, Burrus MT, Weiss DB, Yarboro SR. Applications of local antibiotics in orthopedic trauma. *Orthop Clin North Am.* 2015; 46:495-510.
  19. Brooks JP, Ghaffari G. Idiopathic CD4 lymphocytopenia. *Allergy Asthma Proc.* 2016; 37:501-504.
- (Received May 24, 2017; Revised June 13, 2017; Accepted July 11, 2017)